

# A Stage 4 Hepatoid Adenocarcinoma of the Endometrium: A Case Report and Review of Literature

Duygu ALTIN<sup>1</sup>, Ayca KIRMIZI<sup>2</sup>, Cevriye CANSIZ ERSOZ<sup>2</sup>, Salih TASKIN<sup>1</sup>, Bulent BERKER<sup>1</sup>, Firat ORTAC<sup>1</sup>

Ankara, Turkey

## ABSTRACT

We report a case of 72-year-old woman who was hospitalized with vaginal bleeding and abdominal pain. Magnetic resonance imaging showed tumor both in endometrial cavity and ovaries with multiple distant metastasis. Her serum alpha-fetoprotein level was >54000 ng/mL. Total abdominal hysterectomy with bilateral salpingo-oophorectomy, total omentectomy, appendectomy, bilateral pelvic and paraaortic lymph node dissection, a 20 cm ileal resection with ileal anastomosis, metastasectomy were performed and peritoneal washing was obtained. The pathologic diagnosis was endometrial hepatoid adenocarcinoma. Because of her poor medical condition, she received only palliative chemotherapy. After two days of 5-fluorouracil she died within 2 months. Hepatoid adenocarcinomas are extrahepatic neoplasms that exhibit features of hepatocellular carcinoma. It was first reported as gastric neoplasm but is seen in many different organs and its frequency is increasing. To date only 11 cases of hepatoid adenocarcinoma of the endometrium were reported. It has a poor prognosis and there isn't an effective treatment yet.

**Keywords:** Alpha-fetoprotein, Chemoradiotherapy, Adjuvant, Endometrial carcinoma, Hepatoid adenocarcinoma

*Gynecol Obstet Reprod Med* 2018;24(1):56-59

## Introduction

Hepatoid adenocarcinomas are alpha-fetoprotein (AFP) producing extrahepatic neoplasms which exhibit features of hepatocellular carcinoma (HCC) (1). Hepatoid adenocarcinomas of stomach, lungs, kidneys, ovaries and many other various organs had been previously described (2), but hepatoid adenocarcinoma of the endometrium is very rare. To our knowledge this is the 12th case of hepatoid adenocarcinoma of the endometrium.

## Case Report

A 72 - year-old woman admitted to a local hospital with vaginal bleeding and abdominal pain. She had diabetes mellitus which was on control with oral antidiabetics. The patient had no other medical history of note. Her abdominal ultrasonography showed 57x41 mm multiloculated solid mass in right adnexal region and her liver was normal. Pelvic magnetic resonance imaging (MRI) revealed a 4 cm tumor and fluid in endometrial cavity (Figure 1), 8 cm heterogeneous,


<sup>1</sup> Department of Gynecology and Obstetrics Ankara University School of Medicine, Ankara

<sup>2</sup> Department of Pathology Ankara University School of Medicine Ankara

Address of Correspondence: Duygu Altin  
Department of Gynecology and  
Obstetrics Ankara University School of  
Medicine 06080 Cebeci, Ankara, Turkey  
duyguo@ada.net.tr

Submitted for Publication: 15. 02. 2017

Accepted for Publication: 30. 03. 2017

Access this article online	
Quick Response Code:	Website: <a href="http://www.gorm.com.tr">www.gorm.com.tr</a> e- mail: <a href="mailto:info@gorm.com.tr">info@gorm.com.tr</a>
	DOI:10.201613/GORM.2017.678

**How to cite this article:** Altin D, Kirmizi A, Cansiz Ersoz C, Taskin S, Berker B, Ortac F. A Stage 4 Hepatoid Adenocarcinoma of the Endometrium: A Case Report and Review of Literature. *Gynecol Obstet Reprod Med* 2018;24(1):56-59

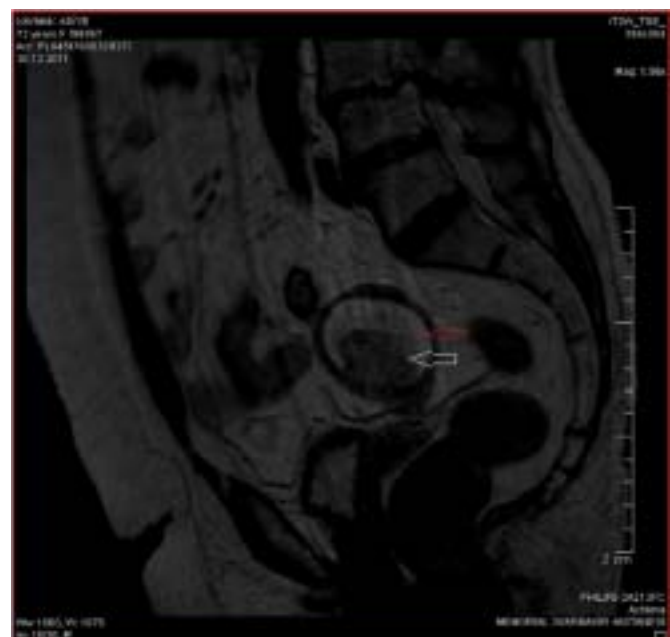


Figure 1: MRI showing 4 cm tumor (white arrow) and fluid (red arrow) in endometrial cavity

multiloculated semisolid mass in right ovary, 3 cm solid lesion in the left ovary, 4.5 cm metastatic implant in Douglas and minimal ascites she was then referred to our hospital. The serum AFP level was >54000 ng/mL (normal <9), CA125 level was 158.4 U/mL (normal <35). CEA, CA15-3 and CA19-9 levels were within the normal range. It was thought as primary ovarian cancer; therefore, endometrial sampling was not done.

At laparotomy, it was seen that uterus was enlarged, there were a necrotic mass in right ovary, palpable pelvic and para-aortic lymph nodes, tumoral implants on sigmoid colon's serosa and in Douglas and tumoral invasion to an ileal segment. Peritoneal surfaces were disease free. Total abdominal hysterectomy with bilateral salpingo-oophorectomy, total omentectomy, appendectomy, bilateral pelvic and paraaortic lymph node dissection, a 20 cm ileal resection with ileal anastomosis, metastasectomy were performed and peritoneal washing was obtained.

The pathology specimen revealed an endometrial polypoid tumor (Figure 2) with lymphovascular invasion, myometrial invasion and lots of tumor nodules on salpinges, parametrium, omentum and peritoneum. The tumor was made of sheets of atypical cells with large, eosinophilic-clear cytoplasm (Figure 3). Tumor showed diffuse positivity with AFP (Figure 4a), focal positivity with hepatocyte Ag (Figure 4b) and diffuse positivity with adenocarcinoma markers such as pCEA, BER-EP-4. (Figure 4c). The histopathological examination revealed poorly differentiated adenocarcinoma with extensive hepatoma-like features and the final diagnosis was hepatoid adenocarcinoma of the endometrium.

She was discharged from hospital on postoperative day 11. She admitted to our hospital one month after the operation with abdominal distension and fatigue. Massive ascites was detected. Because of the surgical site infection, ciprofloxacin + ampicillin/sulbactam treatment was administered. Her serum AFP level was still >54000 ng/mL. She was transferred to medical oncology department to receive chemotherapy. Paclitaxel + carboplatin regimen was planned for the patient. But her infection proceeded to cellulitis and her biochemical results got worse (renal and hepatic function tests increased progressively). Her antibiotherapy was changed to cefepime + teicoplanin + metronidazole. On her new computed tomography (CT) progression of disease on peritoneal surfaces and mesentery was determined. There was a 5 cm subcapsular hepatic metastasis also. Pleural effusion also developed although chest CT showed no metastasis. Because paclitaxel + carboplatin regimen couldn't be administered, palliative chemotherapy was planned and she was given 5-fluorouracil (750 mg/day) on postoperative day 60 and 61. The next day she died. Her creatinine level was 7.7 mg/dL and total bilirubin level was 10.7 mg/dL on the day she died.

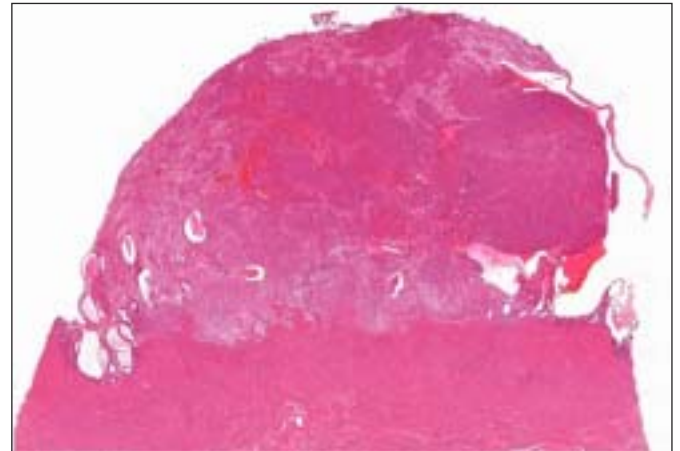


Figure 2: Endometrial polypoid tumor

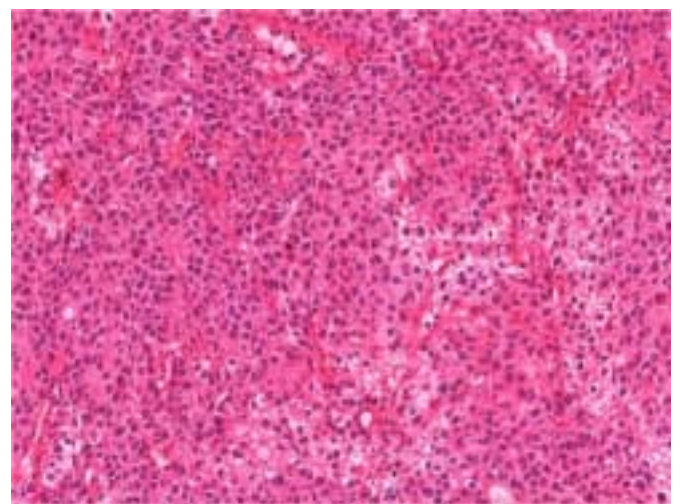


Figure 3: The tumor was made of sheets of atypical cells with large, eosinophilic-clear cytoplasm

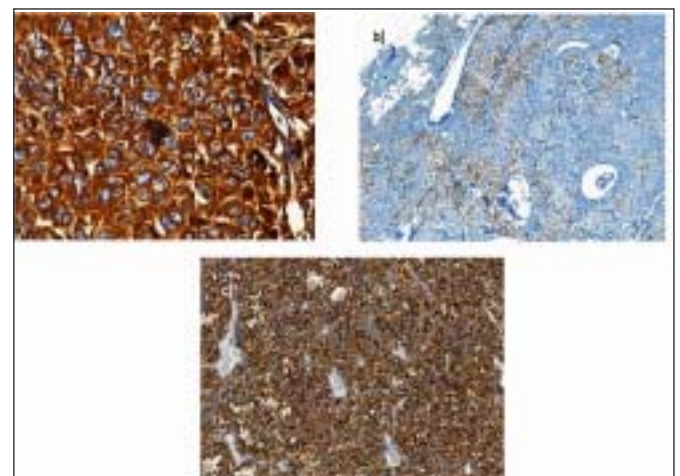


Figure 4: IHC staining of the tumor, a: Diffuse positivity with AFP, b: Focal positivity with hepatocyte Ag, and c: Diffuse positivity with pCEA

## Discussion

Hepatoid adenocarcinomas have been reported in various organs. It is usually diagnosed at older ages and prognosis is

poor regardless of its origin (3). Median age at diagnosis is 65 years (range, 21-88), one-year survival is about 55% and median overall survival has been reported to be 11 months (range, 0.1-102). The outcome is similar for endometrial hepatoid adenocarcinomas (Table 1). Mean age at diagnosis is 67.09 and median age was 66 (range, 60-82) for 11 patients. Five of the patients died of disease (range, 2-32 months), 4 of them were

disease free at the time of reporting as far as we know. For 3 patients we couldn't get information about the outcome.

The AFP levels ranged between 280.3 and 90508 ng/mL. Tumor cells also show AFP expression immunohistochemically. Because of strong AFP expression, it is difficult to make differential diagnosis between yolk sac tumor and hepatoid

Table 1: Summary of the endometrial hepatoid adenocarcinoma cases

Authors	Age (years)	Preoperative AFP value (ng/mL)	Surgery	Adjuvant therapy	Histology, Stage	Outcome
Hoshida et al. (4)	66	16170	TAH BSO + BPLND	RT	Endometrioid+ hepatoid adenoca, Stage 3C1	Died 32 months after surgery
Yamamoto et al. (5)	62	280.3	TAH BSO + LİVER BX	Cyclophosphamide + doxorubicin + cisplatin	Endometrioid + hepatoid adenoca, Stage 4B	Died 3 months after surgery with lung metastasis
Toyoda et al. (6)	60	31950	TAH BSO + BP-PALND	Cyclophosphamide+ doxorubicin + cisplatin After met etoposide	Endometrioid + hepatoid adenoca, Stage 3C2	Died 12 months after surgery with lung metastasis
Adams et al. (7)	66	351 (on po day 4)	TAH BSO + BP-PALND + PW	Cyclophosphamide + doxorubicin + cisplatin	Endometrioid+ hepatoid adenoca, Stage 1B	Disease free for 8 years
Takano et al. (8)	63	5060	TAH BSO + BP-PALND	Paclitaxel + carboplatin	Carcinosarcoma + hepatoid adenoca, Stage 1A	Disease free for 12 months
Takahashi et al. (9)	68	2800	TAH BSO	NA	Carcinosarcoma + hepatoid adenoca, Stage 2B	NA
Takeuchi et al. (10)	61	453	TAH BSO + BP-PALND + OMM + PW	Paclitaxel + carboplatin	Endometrioid + hepatoid adenoca, Stage 4B	Disease free for 12 months
Kawaguchi et al. (11)	63	10131	TAH BSO + BPLND	Paclitaxel + carboplatin	Carcinosarcoma + hepatoid adenoca, Stage 2B	Disease free for 12 months
Kawaguchi et al. (11)	82	401	TAH BSO + PW	Non	Carcinosarcoma + hepatoid adenoca, Stage 1B	Died 12 months after surgery with lung metastasis
Hwang et al. (12)	75	90508	TAH BSO + BP-PALND + PW	NA	NA	
Wu et al. (13)	Couldn't attained					
Present case	72	>54000	TAH BSO + BP-PALND + OMM + ileal resection with anastomosis + metastasectomy + PW	5-FU	Endometrioid + Hepatoid adenoca, Stage 4B	Died 2 months after surgery

Adenoca: Adenocarcinoma, BPLND: Bilateral pelvic lymph node dissection, BPPALND: Bilateral pelvic para-aortic lymph node dissection, BX: Biopsy, OMM: Omentectomy, PW: Peritoneal washing, RT: Radiotherapy, TAH BSO: Total abdominal hysterectomy with bilateral salpingo-oophorectomy, NA: Not available



adenocarcinoma. Since the tumor had diffuse hepatoid morphology with no features of yolk sac tumor and showed immunohistochemically positivity for hepatoid differentiation, it was diagnosed as hepatoid adenocarcinoma.

There is a need for adjuvant therapy because it is an aggressive tumor. But there isn't a consensus on which therapeutic regimen or agent to use. Some authors used radiation therapy and some used chemotherapy. Some of them gave cyclophosphamide + doxorubicin + cisplatin and some gave paclitaxel + carboplatin as adjuvant chemotherapy. We decided to use paclitaxel + carboplatin regimen since it has higher activity in patients with advanced or recurrent endometrial adenocarcinomas (14) but the patient was in poor medical condition with massive ascites, surgical site infection, rising hepatic and renal function tests, so we couldn't administer the planned chemotherapy regimen. We used 5-fluorouracil for palliation but the patient died before completion of chemotherapy. Although we think that the most appropriate option was chosen according to her situation, the death of the patient might have been due to her poor medical condition and/or toxicity associated with chemotherapy.

More case reports should be reported in order to find most effective regimen in hepatoid adenocarcinomas.

## References

1. Kato K, Suzuka K, Osaki T, Itami M, Tanaka N. Primary hepatoid adenocarcinoma of the uterine cervix. *Int J Gynecol Cancer* 2007 Sep-Oct;17(5):1150-4.
2. Lazaro J, Rubio D, Repolles M, Capote L. Hepatoid carcinoma of the ovary and management. *Acta Obstet Gynecol Scand* 2007;86(4):498-9.
3. Metzgeroth G, Ströbel P, Baumbusch T, Reiter A, Hastka J. Hepatoid adenocarcinoma - review of the literature illustrated by a rare case originating in the peritoneal cavity. *Onkologie* 2010;33(5):263-9.
4. Hoshida Y, Nagakawa T, Mano S, Taguchi K, Aozasa K. Hepatoid adenocarcinoma of the endometrium associated with alpha-fetoprotein production. *Int J Gynecol Pathol* 1996 Jul;15(3):266-9.
5. Yamamoto R, Ishikura H, Azuma M, Hareyama H, Makinoda S, Koyama Y, et al. Alpha-fetoprotein production by a hepatoid adenocarcinoma of the uterus. *J Clin Pathol* 1996 May;49(5):420-2.
6. Toyoda H, Hirai T, Ishii E. Alpha-fetoprotein producing uterine corpus carcinoma: a hepatoid adenocarcinoma of the endometrium. *Pathol Int* 2000 Oct;50(10):847-52.
7. Adams SF, Yamada SD, Montag A, Rotmensch JR. An  $\alpha$ -fetoprotein-producing hepatoid adenocarcinoma of the endometrium. *Gynecol Oncol* 2001 Nov;83(2):418-21.
8. Takano M, Shibasaki T, Sato K, Aida S, Kikuchi Y. Malignant mixed mullerian tumor of the uterine corpus with alpha-fetoprotein-producing hepatoid adenocarcinoma component. *Gynecol Oncol* 2003 Nov;91(2):444-8.
9. Takahashi Y, Inoue T. Hepatoid carcinoma of the uterus that collided with carcinosarcoma. *Pathol Int* 2003 May;53(5):323-6.
10. Takeuchi K, Kitazawa S, Hamanishi S, Inagaki M, Murata K. A case of alpha-fetoprotein-producing adenocarcinoma of the endometrium with a hepatoid component as a potential source for alpha-fetoprotein in a postmenopausal woman. *Int J Gynecol Cancer* 2006 May-Jun;16(3):1442-5.
11. Kawaguchi R, Furukawa N, Yamada Y, Ooi H, Kobayashi H. Carcinosarcoma of the uterine corpus with alpha-fetoprotein-producing hepatoid adenocarcinoma: a report of two cases. *Case Rep Oncol* 2011;4(2):358-62.
12. Hwang JH, Song SH, Kim YH, Shin BK, Lee JK, Lee NW, et al. Primary hepatoid adenocarcinoma of the endometrium with a high alpha fetoprotein level. *Scott Med J* 2011 May;56(2):120.
13. Wu QY, Wan XY, Xie X, Lu BJ. Endometrial hepatoid adenocarcinoma: a rare cause of elevated serum  $\alpha$ -fetoprotein. *J Obstet Gynaecol Res* 2014 Mar;40(3):873-7.
14. Fleming GF. Systemic chemotherapy for uterine carcinoma: metastatic and adjuvant. *J Clin Oncol* 2007 Jul 10;25(20):2983-90.